

## Clinical Study of Ocular Morbidity in Head Injury Patients At Tertiary Care Unit, Andhra Pradesh

Dr. Isvs Prasada Rao<sup>1</sup>, Co-Authors: Dr. Pidakala Shyam Sundar<sup>2</sup>, Dr. Vaidehi<sup>3</sup>  
Dr. Parameswari<sup>3</sup>

<sup>1</sup>Associate professor, Department of Ophthalmology, Andhra Medical College, Dr. NTR University of Health Sciences, India

<sup>2</sup>Assistant Professor, Department of Ophthalmology, Andhra Medical College, Dr. NTR University of Health Sciences, India

<sup>3</sup>Post Graduates, Department of Ophthalmology, Andhra Medical College, Dr. NTR University of Health Sciences, India

---

**Abstract:** Head trauma is common in our modern era of motorized transport. Over 50% of all trauma deaths are associated with head injury and close to 60% of vehicular trauma deaths are due to head injuries<sup>1</sup>. Head injuries are frequently associated with ophthalmic manifestations and consequent morbidity<sup>2</sup>. The present study was undertaken to evaluate

the pattern and clinical profile of ocular and visual complications in patients with Head injuries in Government Regional Eye Hospital, KGH, Visakhapatnam. The present study is a hospital based cross-sectional clinical study. done from January 2013- Jan 2015. A total Of 124 cases were included in the study. 11 cases had bilateral involvement. So, total number of eyes was 135 eyes. Among 124 patients only 18 patients were female (14.51 %) and rest 88 were males (85.49 %). incidence of ocular manifestations in head injury patients are more common in young adult population i.e. 21 to 40 years. Both neuroophthalmic manifestations and bony injury to the orbit were more common in patients with severe head injuries with low GCS scores. Hence a keen and careful observation of the ocular features in a patient with head injury not only helps in managing the ophthalmic injuries but can also help in prognosis of the patient and as a result in better management of patient.

**Keywords:** Morbidity, Ocular Trauma, Road Traffic Accidents, Visual Acuity

---

### I. Introduction

Head trauma is common in our modern era of motorized transportation. Over 50% of all trauma deaths are associated with head injury and close to 60% of vehicular trauma deaths are due to head injuries<sup>1</sup>. Head injuries are frequently associated with ophthalmic manifestations and consequent morbidity<sup>2</sup>. The role of ocular injuries secondary to head trauma in the causation of blindness has become a subject of immense importance. Early recognition and clinical correlation of ophthalmic manifestations is important in early localization of the site of injury, ongoing assessment management and prognosis of the patient with head injury. The present study was undertaken to evaluate the pattern and clinical profile of ocular and visual complications in patients with Head injuries in Government Regional Eye Hospital, KGH, Visakhapatnam.

### II. Aim

To study the ocular morbidity in patients with Head injuries at a Tertiary care hospital

### III. Objectives

3.1. To describe various patterns of ocular morbidity in patients with Head injuries.

3.2. To describe ocular morbidity in relation to age, sex and types of Head injuries

### IV. Materials & Methods

4.1. Study Design: Hospital based cross-sectional clinical study.

4.2. Study Period: From January 2013- Jan 2015

4.3. Study Subjects: All the patients of head injury with ocular manifestations during the study period were included in the study

4.4 Study Setting: IPD&OPD's of Neurosurgery ,Surgery and Ophthalmology departments at King George Hospital, Visakhapatnam, AP.

### V. Inclusion criteria

Head injury patients with ophthalmic manifestations

**VI. Exclusion criteria**

Very seriously ill patients and non cooperative patients

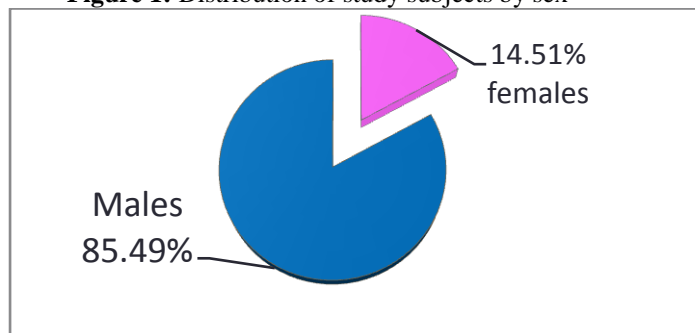
**VII. Data collection**

The present study was carried out after obtaining Approval from the Institutional Review Board (ethics committee of the institution), and consent from study participants.

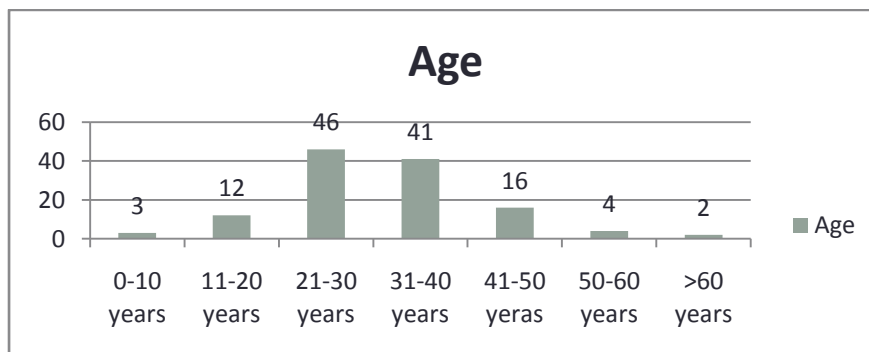
A cross-sectional study of all patients of head injury with ocular manifestations attended at King George Hospital, Visakhapatnam during a period between January 2013- January 2015 was done. A total of 124 patients of which 11 patients had bilateral involvement and thus contributed total number of eyes affected 135 were identified. The following data was recorded – age, sex, type & duration of Head injury, ocular manifestations based on symptoms and signs Glasgow coma scale visual Acuity, Fundus examination by using direct or indirect ophthalmoscope. The following signs of head injury and ocular injury were looked for specifically. Vitreous haemorrhage, Posterior vitreous detachment, Papilloedema, Optic atrophy, Retinal edema/haemorrhages/tears, Retinal detachment, Choroidal rupture, Neuroimaging studies: X-ray, CT scan/MRI and B-scan as felt necessary in individual cases.

**VIII. Results**

**Figure 1:** Distribution of study subjects by sex

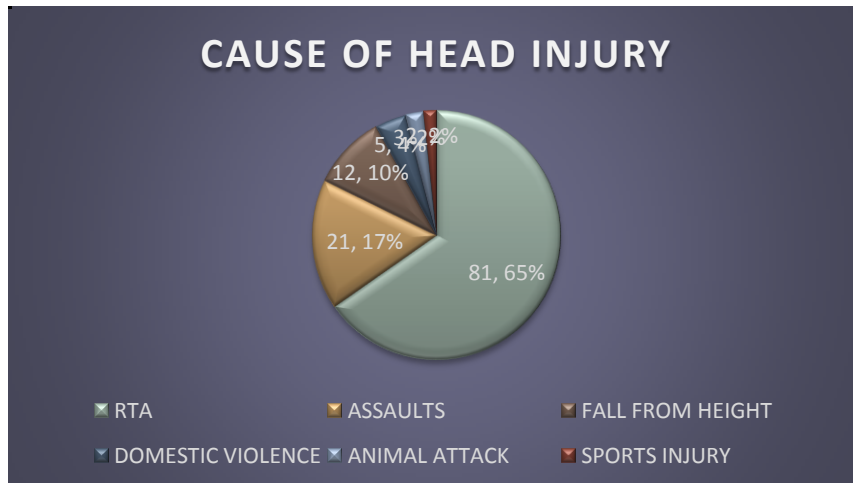


**Figure 2:** Distribution of study subjects by sex



Most of them were males(85.49%) and affected age group were 21-30 years( 46% ) followed by 31-40 years (41%)

**Figure 3:** Distribution of study subjects by cause of Head injury .



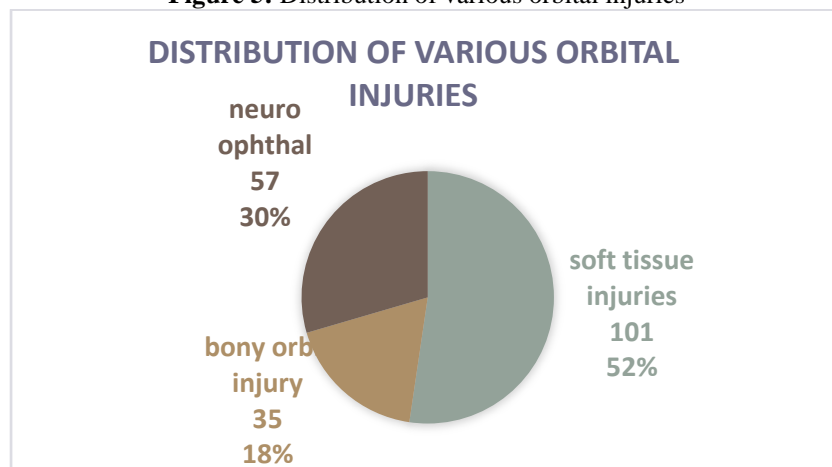
Most of them were (81.65%) victims of RTA followed by Assaults(21.17%) Majority of RTA were two wheelers (54.99%) followed by four-wheeler (22.53%), Pedestrians (15.49%), Auto taxi passengers (7.04%)

**Table 4:** Catagorywise distribution of RTA

Category	Number	Percentage
Two wheeler	39	54.99
Auto taxi	5	7.04
Four wheeler	16	22.63
Pedestrians	11	15.49

Majority of RTA were two wheelers (54.99%) followed by four-wheeler (22.53%), Pedestrians (15.49%), Auto taxi passengers (7.04%)

**Figure 5:** Distribution of various orbital injuries

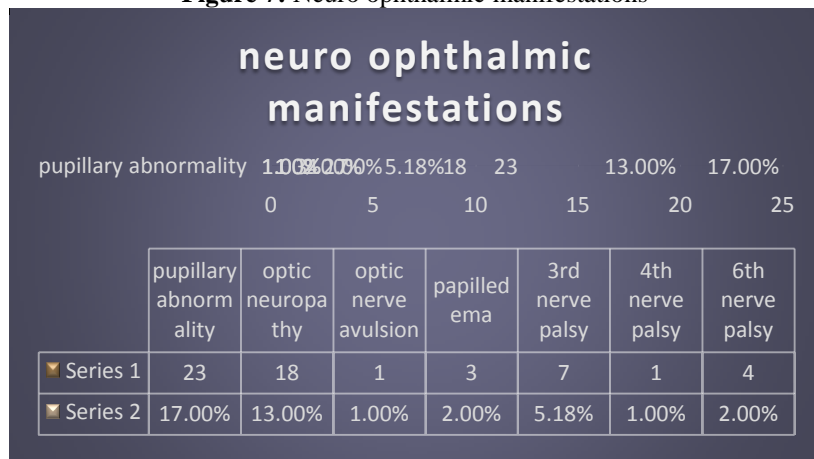


**Table 6:** Different patterns of ocular morbidity

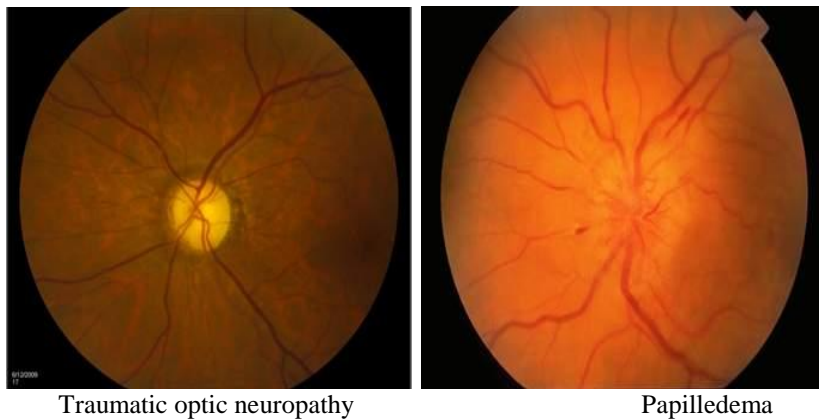
	UNILATERAL	BILATERAL
Lid laceration	13{9.62%}	1{0.74%}
Sub conjunctival heammorrhage	41{30.3%}	4{2.96%}
Echymosis	18{13.33%}	3{2.22%}
chemosis	12{8.88%}	2{1.48%}
Lid oedema	6{4.44%}	1{0.7%}
Sch+ecchymosis	16{11.85%}	
Lid laceration+ sch	14{10.37%}	
Chemosis+lid laceration	33{24.44%}	
Sch+orbital injuries	14{10.37%}	
Neuro+orbit+Sch	5{3.7%}	

Most of the injuries were soft tissue injuries of globe and adnexa. Commonest finding was subconjunctival haemorrhage(30.3%) followed by chemosis and lid lacerations(24.4%).

**Figure 7: Neuro ophthalmic manifestations**

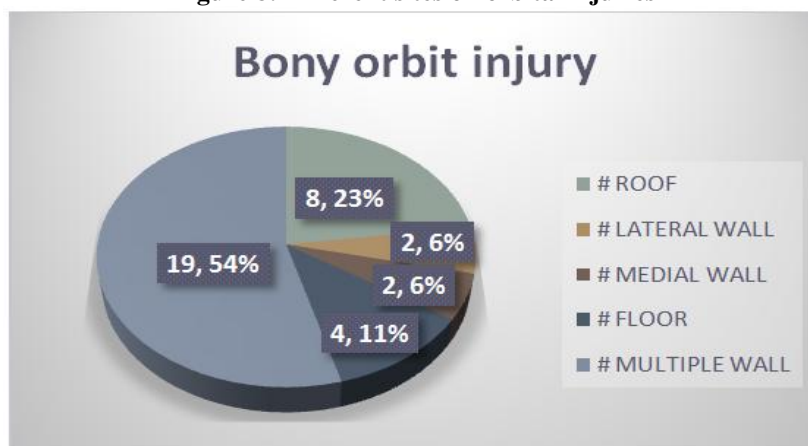


Of the neuroophthalmic findings pupillary abnormalities were most common seen in 23 (17%) cases. Ocular motor nerve palsies were second most common neuroophthalmic abnormalities. It accounted for 7 (5.18%) cases. Traumatic optic neuropathy was diagnosed in 18 (13%) cases with severe visual impairment. It manifested with loss of visual acuity in one eye accompanied with the presence of an ipsilateral afferent pupillary defect. Optic nerve avulsion was observed in one case only. Papilloedema was observed in 3 cases. Pupillary abnormality of various types were observed in 23 cases in the present study which was the most common neuroophthalmic finding in this study.



In the present study, optic nerve avulsion was found only in one case which had presented with a ring hemorrhage around the optic disc on ophthalmoscope. Traumatic optic neuropathy was found only in only 18 cases.

**Figure 8: Different sites of orbital injuries**



### 8.1. Neuroimaging

Among the 57 patients having neuroophthalmic manifestations 12 patients did not show any abnormality on neuroimaging.

### 8.2. Visual acuity

In the present study, visual acuity at the time of presentation was 6/36-6/60 in 61 eyes (45.18%),  $\leq 6/60$  in 29 eyes (21.48%) and 6/6-6/18 in 19 eyes (14.07%). Visual acuity could not be recorded in 26 eyes (25 cases) due to seriously ill condition of the patients.

### 8.3. Glasgow Coma Scale (GCS) Score

All the patients of head trauma with ocular manifestations were evaluated for GCS score at the time of admission to hospital. Three groups were made according to the GCS scoring. The patients were classified into three groups

1. Mild Head Injury- Gcs [14-15]
2. Moderate Head Injury- Gcs [9-13]
3. Severe Head Injury- Gcs [3-8]

**Table 9:** Type of head injury in relation to GCS score

Type Of Injury	GCS	No. Of Patients
Mild Head Injury	14-15	79
Moderate Head Injury	9-13	28
Severe Head Injury	3-8	17

## IX. Discussion

The present study showed that more than 2/3 of ocular morbidity seen in males because they involve more frequently in outdoor activities than females which was similar to other studies like N.S.D Raju et al<sup>(3)</sup> and Odebode et al<sup>(4)</sup> reported 64.9 males, 35.1% females respectively.

In our study, incidence of ocular manifestations in head injury patients was more common in young adult population i.e. 21 to 40 years. This finding was similar to the findings in other studies like A.R. Kulkarni et al<sup>(5)</sup> showed young adult males (21-30 years) were more vulnerable.

Ocular and orbital injuries: The present study found soft tissue injuries of globe and adnexa were more common which was similar to other studies. The present study showed sub conjunctival haemorrhage was (67.4%) followed by chemosis of conjunctiva(54.8%), lid oedema(47.4%) lid ecchymosis (40%) and lid lacerations(14.1%). These findings were different from other studies like B.Sharma et al<sup>(6)</sup> found, where ecchymosis was found to be( 51.85%) followed by sub conjunctival hemorrhage (44.4%), lid edema (41.5%), lacerated wound( 22.59 %),AR Kulkarni et al<sup>(5)</sup>,found ecchymosis (27%) was the most common finding, followed by subconjunctival haemorrhage (19%).

Neuro-Ophthalmic injuries- The present study showed Neuro-ophthalmic morbidity was 42.2% which was higher than other studies like Keane et al<sup>(7)</sup> where it was found to be 16.7%, Sabates et al<sup>(8)</sup> and Kowalek et al<sup>(9)</sup> found to be 7.7% 26.1% respectively. In the present study only one patient was diagnosed with trochlear nerve palsy and it was unilateral and patient complained of diplopia. The abducent nerve was the most commonly affected nerve in the present study which was similar to other studies like B.Sharma et al<sup>(6)</sup>, and Smruthi et al<sup>(10)</sup>.

Bony orbital injury – in our study it was found to be 20.3%, which was higher than study conducted by Cossman et al<sup>(14)</sup>, where it was found to be 5%.

Glasgow coma scale (GCS) score

1. Mild Head Injury- Gcs [14-15]
2. Moderate Head Injury- Gcs [9-13]
3. Severe Head Injury- Gcs [3-8]

Mortality rate in our study was about 12.09%. It was similar to the finding of AR Kulkarni et al<sup>(5)</sup> who found a mortality rate of 13%. All of them had ocular involvement with neurological significance.

Limitations of the study

1. VEP(visual evoked potential) could not be done due to its non-availability.
2. Long term manifestations of head injury and visual outcome could not be assessed due to irregular follow up visits of patients.
3. Neurosurgeon consultation is mandatory for each case of head injury.

## **X. Conclusion**

The present study reveals that soft tissue injuries to globe and adnexa like subconjunctival haemorrhage, eyelid oedema, chemosis, ecchymosis and eyelid lacerations are the most common ocular manifestations in head injuries. Neuroophthalmic manifestations were less commonly found, most common being pupillary abnormalities, followed by oculomotor nerve palsies. Both neuroophthalmic manifestations and bony injury to the orbit were more common in patients with severe head injuries with low GCS scores. Both these findings were also more common in patients who had fatal outcome. So, it is observed that patients with neuroophthalmic manifestations and bony orbital injuries have poor prognosis and should be managed carefully. Hence a keen and careful observation of the ocular features in a patient with head injury and also neurosurgeon consultation is mandatory for each case of ocular trauma. It not only helps in managing the ophthalmic injuries but can also help in prognosis of the patient and as a result in better management of patient.

## **References**

- [1]. Van Stavern GP, Biousse V, Lynn MJ, Simon DJ, Newman NJ. Neuro-Ophthalmic manifestations of head trauma. *J Neuro-Ophthalmol* 2001; 21 (2): 112-117.
- [2]. Chaudhuri Z, Pandey PK, Gupta R & Chauhan D. Profile of ocular morbidity associated with head injury. *AIOC Proceedings. Miscellaneous* 2002; p 609.
- [3]. NSD Raju Ocular manifestations in head injuries Year: 1983 | Volume : 31 | Issue : 6 | Page : 789-792
- [4]. Odebode TO, Ademola-Popoola DS, Ojo TA, Ayanniyi AA (2005) Ocular and visual complications of head injury. *Eye (Lond.)* 19:561–566
- [5]. A R Kulkarni<sup>1</sup>, S P Aggarwal<sup>1</sup>, R R Kulkarni<sup>2</sup>, M D Deshpande, P B Walimbe- and A S Labhsetwar- Ocular manifestations of head injury *Eye (Lond)*. 2005 Dec;19(12):1257-63
- [6]. Sharma B, Gupta R, Anand R, Ingle R. Ocular manifestations of head injury and incidence of post-traumatic ocular motor nerve involvement in cases of head injury: *Int Ophthalmol*. 2014 Aug;34(4):893-900. doi: 10.1007/s10792-014-9898-8.
- [7]. Keane JR (1989) Neurologic eye signs following motor vehicle accidents. *Arch Neurol* 46:761–762
- [8]. Sabates N, Gonce M, Farris B (1991) Neuro-ophthalmological findings in closed head trauma. *J Clin Neuroophthalmol* 11:273–277
- [9]. Kowal L (1992) Ophthalmic manifestations of head injury. *Aust NZ J Ophthalmol* 20:35–40
- [10]. 10Dr. Smruthi I , Dr. Ajay S. Hatti2 :Ocular Manifestations in Head Injury at SSIMS & RC *International Journal of Science and Research (IJSR) ISSN (Online): 2319-7064*